

Conservative Management of a Solitary Kidney in a Patient with Grade IV Renal Injury: A Case Report

VILAS PANDURANG SABALE¹, UJJWAL BHARDWAJ², DEEPAK MANE³, ABHIRUDRA MULAY⁴, VIKRAM SATAV⁵

ABSTRACT

The kidney is the most frequently injured organ in the genitourinary system, accounting for 1 to 5% of all trauma cases. The mechanism of injury can be either blunt or penetrating. Management strategies depend on the American Association for the Surgery of Trauma (AAST) grade of injury. For injuries upto AAST grade IV conservative management is employed, whereas grade 5 requires surgical exploration. The present case report discusses a rare and challenging case of traumatic injury to a solitary kidney in a 26-year-old male, resulting from a blunt horse kick. The patient presented with severe right-sided abdominal pain and anuria for eight hours, alongside haemodynamic instability and clinical signs of renal trauma. Initial imaging revealed a grade IV renal injury with haemoperitoneum and a solitary right kidney. Conservative management was prioritised to preserve the solitary kidney. Resuscitative measures, including volume expansion, blood transfusions, and dialysis sessions, were employed, while complications such as acute kidney injury and acute respiratory distress syndrome were managed by a multidisciplinary team. A retrograde pyelogram later revealed mild pelvicalyceal dilation and contrast leakage, leading to successful decompression with silicone double-J stenting (DJ) stenting. The patient's condition improved, with the restoration of urine output and normalisation of serum creatinine levels. Follow-up demonstrated complete recovery without further complications. The present case emphasises the importance of a conservative approach, multidisciplinary collaboration, and close monitoring in managing high-grade renal trauma involving a solitary kidney, thereby avoiding the need for nephrectomy and lifelong renal replacement therapy.

Keywords: Haemoperitoneum, Nephrectomy, Renal trauma, Urine output

CASE REPORT

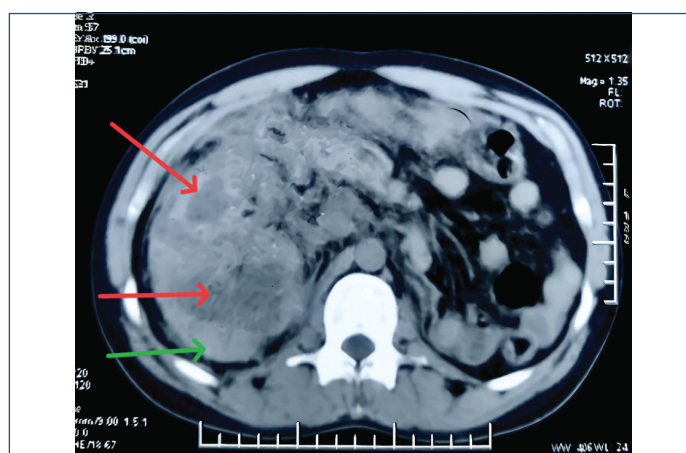
A 26-year-old male presented to the Emergency Department with complaints of severe right-sided abdominal pain and an inability to pass urine for eight hours, following a blunt horse kick injury to the right-side of his abdomen while playing a traditional village sport in the Maharashtra state of India. There was no history of passing blood per urethra.

On examination, he was conscious and oriented, moderately built, with a pulse rate of 110 beats per minute and a feeble quality. His blood pressure was 90/60 mmHg, and he appeared slightly pale. Severe tenderness and bruising were present over the right loin region, but no lump or fullness was observed. The urinary bladder was not palpable.

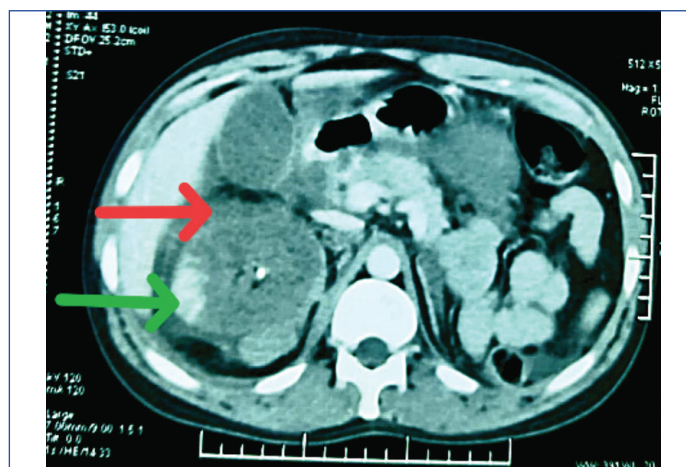
An immediate abdominal ultrasound was performed, which suggested mild to moderate free fluid in the peritoneal cavity, indicative of haemoperitoneum. The right kidney was enlarged, measuring 16 cm by 6 cm, with raised echogenicity. Minimal perinephric collection was noted, and the left kidney was not visualised. Initial blood reports indicated a haemoglobin level of 9.6 g/dL and a serum creatinine level of 1.4 mg/dL, while the rest of the laboratory parameters were within normal limits.

Resuscitation began immediately with volume expanders and the transfusion of two units of packed red cells. A Foley catheter was placed, but no urine output was observed. Once the patient was stabilised, a Contrast-enhanced Computed Tomography (CECT) of the abdomen and pelvis was performed, which suggested an enlarged right kidney measuring 17 cm by 9 cm (green arrow), with multiple areas of large intraparenchymal contusion and laceration extending to the collecting system (Grade IV) (red arrow) [Table/Fig-1a]. Multiple areas of renal infarction with haematoma and contrast leakage were noted [Table/Fig-1b,c], along with evidence of renal vein thrombosis. The renal artery appeared normal, and the left kidney was absent.

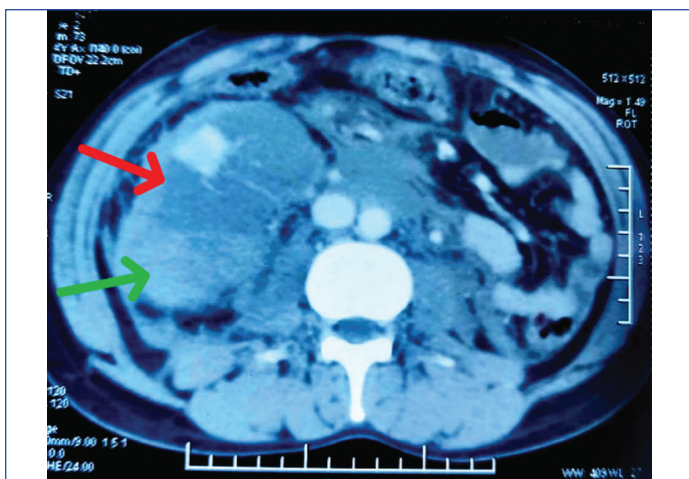
Given the solitary functioning kidney, a decision was made to pursue conservative management to preserve renal function.



[Table/Fig-1a]: Axial section (Non contrast) green arrow- Right enlarged kidney; Red arrow- Intraparenchymal contusion and laceration.




[Table/Fig-1b]: Axial section (Contrast CT) Red arrow-perirenal haematoma; Green arrow- extravasation contrast.



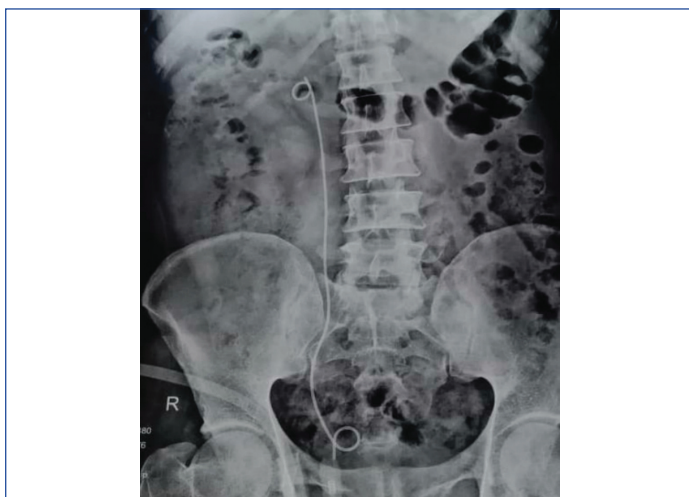[Table/Fig-1c]: Red arrow-renal parenchymal laceration and contusion. Green arrow- right bulky kidney with mild enhancement of renal parenchyma.

Haemodynamic stabilisation was achieved, and the patient was closely monitored in the critical care unit. Intravenous heparin was initiated for renal vein thrombosis at a dose of 5000 IU four times a day. During the Critical Care Unit (CCU) stay, the patient underwent serial measurements of haematocrit, daily renal function assessments, and electrolyte measurements. The highest rise in creatinine was to 12 mg/dL. A total of 14 dialysis sessions and four packed red cell transfusions were performed after consultation with the nephrologist. Meanwhile, the patient developed acute respiratory distress syndrome, which was managed with interventions from respiratory medicine and critical care.

On the 22nd day of stabilisation, the patient began passing 5-10 mL of urine. A Retrograde Pyelogram (RGP) was performed, which showed mild dilatation of the pelvi-calyceal system (blue arrow) along with a leak of contrast from the lower calyx (yellow arrow) [Table/Fig-2]. A right silicone DJ stent was placed, as shown in [Table/Fig-3].



[Table/Fig-2]: Right Retrograde Pyelogram (RGP) Blue arrow-normal opacification of upper calyx, yellow arrow- contrast extravasation from lower calyx.



[Table/Fig-3]: Right DJ stent.

After two days of DJ stent placement, urine output increased significantly, and the creatinine level decreased to a nadir of 1.5 mg/dL. The patient made a complete recovery. Six weeks later, the DJ stent was removed, and an RGP was performed, which showed no contrast leak. The patient is currently under regular follow-up.

DISCUSSION

Unilateral renal agenesis has an incidence of 1 in 2,000 individuals in the worldwide population [1]. The kidney is one of the most frequently injured retroperitoneal organs due to blunt abdominal trauma. Renal trauma accounts for 1-5% of all trauma cases [2]. Although blunt renal injury is infrequent, it is not uncommon. The most common mode of injury is a motor vehicle accident, followed by falls from height and contact sports [3]. According to the American Association for the Surgery of Trauma (AAST), a high-grade kidney injury is defined as either a grade IV or V injury. AAST grade IV refers to parenchymal laceration extending through the renal cortex, medulla, and collecting system, as well as vascular injury to the segmental renal artery or vein and segmental infarction without associated active bleeding. AAST grade V indicates a completely shattered kidney or avulsion of the renal hilum. Most renal injuries are managed conservatively upto AAST grade IV, provided the patient is haemodynamically stable [4]. Trauma to a solitary functioning kidney is a very rare phenomenon. Injury to the solitary kidney can be catastrophic for the patient. The most common mechanism of injury is deceleration injury, which accounts for 90% of cases. Other mechanisms include penetrating or gunshot injuries [5]. A thorough general and clinical examination is mandatory in all cases of renal trauma for optimal patient management. The presence or absence of gross haematuria does not always correlate with the severity of the injury [6]. Non operative management of renal trauma is the treatment of choice for haemodynamically stabilised patients with moderate (grade III) to severe (grade IV) renal injuries [7]. In a similar case reported by Shin H et al., the patient was managed conservatively. However, the patient developed a pseudoaneurysm, resulting in haematuria; coiling of the aneurysm was performed with the help of an interventional radiologist [8]. In present case, no such complication occurred. In another case reported by Marszalek M et al., an initial conservative approach for the management of grade IV renal trauma in a solitary kidney was attempted, but later an operative intervention was performed to evacuate an expanding haematoma [9]. For high-grade solitary kidney injuries, surgical intervention is generally avoided, as it often results in nephrectomy, leading to lifelong dialysis or the need for renal transplantation [9,10].

CONCLUSION(S)

The present case highlights the importance of comprehensive care and conservative management in high-grade renal trauma involving a solitary kidney. Multidisciplinary collaboration enabled the preservation of renal function, avoiding nephrectomy and lifelong renal replacement therapy. The present patient's journey from a critical condition to recovery highlights the value of timely, individualised interventions in such rare and complex scenarios.

REFERENCES

- [1] Westland R, Schreuder MF, Ket JC, van Wijk JA. Unilateral renal agenesis: A systematic review on associated anomalies and renal injury. *Nephrol Dial Transplant*. 2013;28(7):1844-55. Doi: 10.1093/ndt/gft012. Epub 2013 Feb 28. PMID: 23449343.
- [2] Veeratterapillay R, Fuge O, Haslam P, Harding C, Thorpe A. Renal trauma. *J Clin Urol*. 2017;10(4):379-90.
- [3] Erlich T, Kitrey ND. Renal trauma: The current best practice. *Therapeut Adv Urol*. 2018;10(10):295-303.
- [4] Voelzke BB, Leddy L. The epidemiology of renal trauma. *Transl Androl Urol*. 2014;3(2):143-49. Doi: 10.3978/j.issn.2223-4683.2014.04.11. PMID: 26816762; PMCID: PMC4708168.
- [5] Kautza B, Zuckerbraun B, Peitzman AB. Management of blunt renal injury: What is new? *Eur J Trauma Emerg Surg*. 2015;41:251-58.

- [6] Brandes SB, McAninch JW. Urban free falls and patterns of renal injury: A 20-year experience with 396 cases. *J Trauma*. 1999;47(4):643-50. Doi: 10.1097/00005373-199910000-00007.
- [7] Morey AF, Brandes S, Dugi DD, Armstrong JH, Breyer BN, Broghammer JA, et al; American Urological Association. Urotrauma: AUA guideline. *J Urol*. 2014;192(2):327-35. Doi: 10.1016/j.juro.2014.05.004.
- [8] Shin H, Sung AJ, Lee MA, Cho J, Lee GJ, Yu B, et al. Salvation of a solitary kidney in a patient with grade IV renal trauma: A case report. *J Trauma Inj*. 2022;35(Suppl 1):S18-S22.
- [9] Marszalek M, Madersbacher S, Rauchenwald M. Grade IV renal trauma in a patient with a solitary kidney. *Urol Int*. 2008;81(2):241-43. Doi: 10.1159/000144070.
- [10] Wessells H, Suh D, Porter JR, Rivara F, MacKenzie EJ, Jurkovich GJ, et al. Renal injury and operative management in the United States: Results of a population-based study. *J Trauma Acute Care Surg*. 2003;54(3):423-30.

PARTICULARS OF CONTRIBUTORS:

1. Professor, Department of Urology, Dr. D. Y. Patil Medical College Hospital and Research Centre, Pune, Maharashtra, India.
2. Senior Resident, Department of Urology, Dr. D. Y. Patil Medical College Hospital and Research Centre, Pune, Maharashtra, India.
3. Professor, Department of Urology, Dr. D. Y. Patil Medical College Hospital and Research Centre, Pune, Maharashtra, India.
4. Professor, Department of Urology, Dr. D. Y. Patil Medical College Hospital and Research Centre, Pune, Maharashtra, India.
5. Professor, Department of Urology, Dr. D. Y. Patil Medical College Hospital and Research Centre, Pune, Maharashtra, India.

NAME, ADDRESS, E-MAIL ID OF THE CORRESPONDING AUTHOR:

Dr. Ujjwal Bhardwaj,
Senior Resident, Department of Urology, Dr. D. Y. Patil Medical College Hospital and Research Centre, Pimpri, Pune-411018, Maharashtra, India.
E-mail: ujjwal.vicky@gmail.com

PLAGIARISM CHECKING METHODS: [\[Jain H et al.\]](#)

- Plagiarism X-checker: Jan 30, 2025
- Manual Googling: Mar 06, 2025
- iThenticate Software: Mar 08, 2025 (9%)

ETYMOLOGY: Author Origin**EMENDATIONS:** 6**AUTHOR DECLARATION:**

- Financial or Other Competing Interests: None
- Was informed consent obtained from the subjects involved in the study? Yes
- For any images presented appropriate consent has been obtained from the subjects. Yes

Date of Submission: **Jan 29, 2025**Date of Peer Review: **Feb 24, 2025**Date of Acceptance: **Mar 11, 2025**Date of Publishing: **Apr 01, 2025**